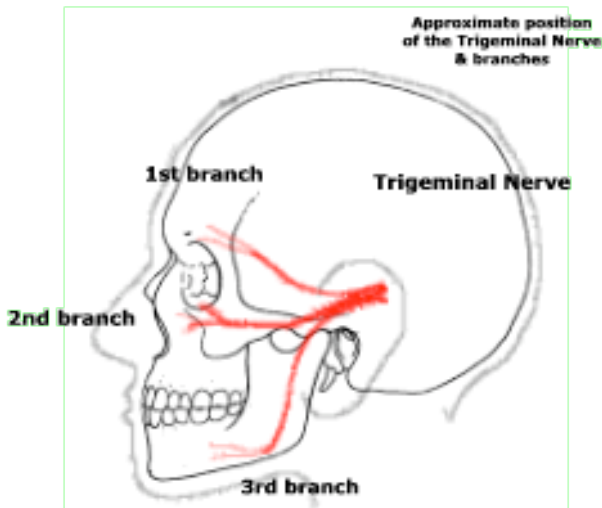




Trigeminal Neuralgia

The most common neurosurgical treated neuralgic pain is Trigeminal Neuralgia. The trigeminal nerve supplies sensation to the skin of the face. It originates at the back part of the brain and goes through three bony holes in the skull to supply three divisions of the face on each side. When the nerve is irritated it produces attacks of sharp pain in the face corresponding with the divisions of the nerve.



CAUSE

There is often no known cause for trigeminal neuralgia. Direct pressure by surrounding pulsatile blood vessels are thought to slowly damage the nerve resulting in neuralgic pain. Occasionally tumours in the region of the trigeminal nerve can present with trigeminal neuralgia. The nerve or its place of origin on the brainstem can itself be affected by a plaque associated with multiple sclerosis.

SIGNS AND SYMPTOMS

The classic description is of severe sharp shooting pain into one or more adjacent regions of the face. It usually affects one side of the face only although occasionally both sides are affected. There are often triggers to pain such as cold air, light touch, and eating. There should be no facial weakness or other neurological symptoms. Sometimes the pain is severe enough to prevent a person eating or drinking requiring urgent hospitalisation for treatment and nutrition.

INVESTIGATIONS

Blood tests

There are no specific blood tests to diagnose an acoustic neuroma. Routine FBE, electrolytes and clotting profiles will be performed prior to operative treatment of trigeminal neuralgia.

Radiological imaging

- CT Head – this is performed to rule out any large mass lesion causing pressure on the trigeminal nerve.
- MRI Head – this is performed to rule out any mass lesion or multiple sclerosis plaques as a cause of trigeminal neuralgia. It will also give good definition for other structures where abnormalities may mimic trigeminal neuralgia.
- MR angiogram – this is sometimes used to demonstrate small vessels coursing around the trigeminal nerve but this is by no means diagnostic.

This condition has a first line treatment of medication, such as Tegretol, and other similar neuralgic pain medication. Once these treatments are at a maximum and symptoms remain severe, neurosurgical treatment is sought.