



## Spinal Tumours

Spinal tumours are made of cells growing and reproducing in an uncontrolled fashion. A benign spine tumour is formed from abnormal cells that form a distinct boundary from the spinal cord. A malignant tumour consists of cells arising from either another part of the body and spreads to the spine or can arise from within the spinal cord itself. The life threatening nature of a malignant tumour depends on both the type of cancerous cells that comprise the tumour and the exact location of the tumour in the spinal cord.

Tumours that arise from cells found normally in the spinal cord or its coverings are primary spine tumours while metastatic tumours are formed by cells originating from a tumour in another part of the body such as lung or breast cancer.

There are three main locations of spinal tumours:

### 1. Extradural (55% of cases)

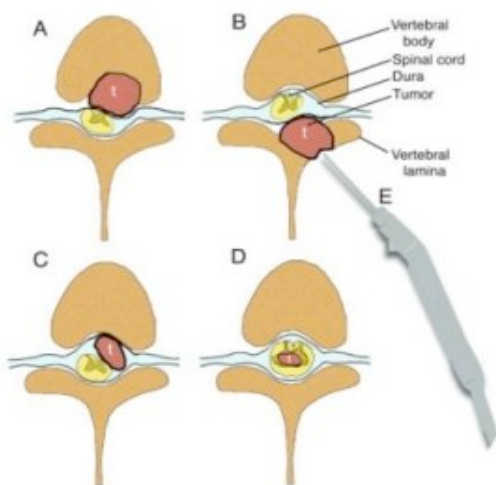
- Arise in bone or tissue around the covering of the spinal cord.

### 2. Intradural extramedullary (40% of cases)

- Arise from within the sack surrounding the spinal cord and nerves but not within the cord or nerve themselves.

### 3. Intramedullary spinal cord tumour (5% of cases)

- Arise from within the spinal cord.



1. Anteriorly extradural based tumour
2. Posteriorly extradural based tumour
3. Intradural extramedullary tumour
4. Intramedullary tumour

Copyright © Oxford University Press, Do you really need back surgery? [www.backpain-guide.com](http://www.backpain-guide.com)

## TYPES OF MALIGNANT SPINE TUMOURS:

### Metastatic

Metastatic spine tumours occur more frequently than primary spine tumours. These malignant spine tumours are formed by cancer cells that originated from a cancer growing in a separate organ of the body before spreading usually to the bone of the spine. The malignant tumours that spread most often to the spine are lung cancer, breast cancer, prostate, and lymphoma (blood) cancer. Metastatic spine tumours may be single or multiple.

### Ependymoma

Ependymoma are the most common form of glioma that is found within the spinal cord at the cervical area and around the clonus near the lower nerve roots.

### Astrocytoma

Astrocytomas are tumours that arise from within the spinal cord (intramedullary) and are less common than occur within the brain.

There are many other types of tumours which are rare and should be discussed with your Neurosurgeon.

## TYPES OF BENIGN SPINE TUMOURS:

### Meningioma

This tumour arises from the strong covering layers surrounding the spine called the meninges (Intradural extramedullary). In general it is slow growing and causes symptoms by localized pressure on the spinal cord. Meningiomas do not frequently invade into the spinal cord or spread. Depending on the size and site of the meningioma treatment may involve monitoring with regular scans, neurosurgery or radiosurgery.

### Neurofibroma

This tumour arises from the spinal nerve as they leave the spinal cord.

There are many other types of tumours which are rare and should be discussed with your Neurosurgeon.



## SIGNS AND SYMPTOMS

A tumour growing in the spine can cause pressure and subsequent damage on the spinal cord and nerves. They may also weaken the bone of the spine. The symptoms depend on the size and location of tumour, as well as the mass effect caused by the abnormal space-occupying lesion and may include:

- Pain
- Focal neurological deficits

### **Pain**

Pain can occur due to the destruction of the bone of the spine or pressure placed upon the spinal nerves. This pain may be within the spinal or spread down either the arms or legs.

### **Focal neurological deficits**

This is dependent on the site of the tumour and may mimic a stroke with weakness, numbness, paralysis, disco-ordination, difficulty walking or losing control of the bladder or bowels.

## INVESTIGATIONS

### **Blood tests**

There are no specific blood tests to diagnose spinal tumours. There may be positive tumour markers in the presence of a metastatic tumour. A routine FBE, electrolytes and clotting profile will be taken prior to neurosurgical intervention.

### **Radiological imaging**

- Plain X-rays may show some changes within the bones of the spine
- CT spine – this is usually the first-line investigation to diagnose the cause of the symptoms
- MRI spine – this is the gold standard for diagnosis of spine tumours giving high detailed definition into the tumour and surrounding neural structures. Occasionally an MRI of the Brain will also be obtained to determine the presence or otherwise of tumour seeding in the CSF (eg medulloblastoma, pineal tumours)

### **Lumbar puncture**

- Is performed in some cases of tumours it may assist in diagnosis and treatment planning.