



## Skull Fracture

A tremendous amount of force is needed to fracture the strong skull bone. As such there is usually a degree of associated head injury with a skull fracture. The weakest point of the skull is around the temple region of the head and this is where most fractures occur.

Skull fractures may be classified numerous ways:

- Simple fracture: the overlying skin is intact
- Compound fracture: the overlying skin is breached/penetrated
- Comminuted fracture: the fractured skull fragment is in several pieces
- Depressed fracture: the fractured skull fragment is pushed down below the remaining skull bone, often into the brain itself.

### CAUSE

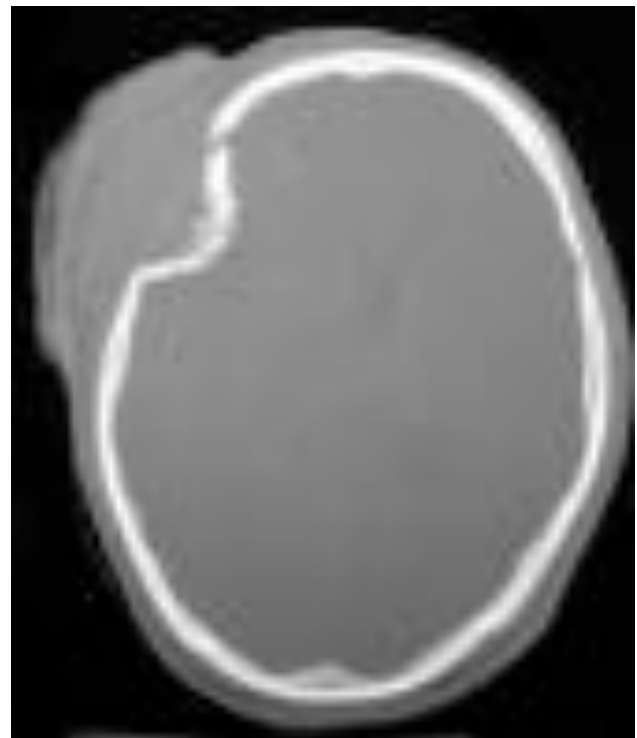
Skull fractures are seen following cases of assault, blunt or penetrating head trauma, motor vehicle accidents or falls. Essentially any event that results in heavy impact to the head may result in skull fractures.

### SIGNS AND SYMPTOMS

There will usually be pain overlying the fracture with associated bruising and swelling to the skin. If there is associated head injury then symptoms may be more specific to the underlying head injury rather than the skull fracture and include, confusion, stroke-like symptoms such as weakness, numbness and speech disturbances, seizures, altered consciousness, coma even death.

### INVESTIGATIONS

The investigation of choice is a CT head with bony windows. This will identify the fracture and any concomitant brain injury also. A skull x-ray is not indicated.



*Skull fracture*