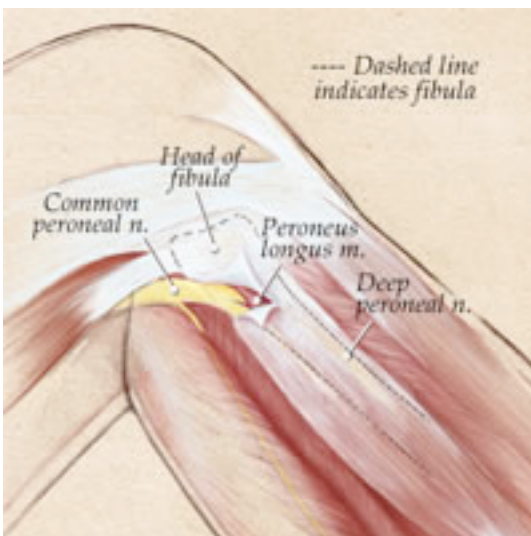




Common Peroneal Nerve Syndrome

The common peroneal nerve is one of the three major nerves that supplies the muscle and feeling of the lower leg. This nerve is formed in the lower lumbar spine and is part of the sciatic nerve. The nerve exits the pelvis and runs down the back of the thigh. Around the level of the knee are the sciatic nerve divides and one of these branches is the common peroneal nerve. The nerve then wraps around the fibula which is the bone which is located on the outside of the knee joint and lower leg. It then passes into the front part of the lower leg. It is within this part of the leg that the nerve supplies the muscles that control the foot and toes. The nerve also gives branches to areas of skin over the lower leg and foot.



Copyright The Dellon Institutes for Peripheral Nerve Surgery™ 2003

CAUSE

The nerve can be compressed in its course around the outer part of the knee. This may be due to:

- Thickening of the ligament over the nerve.
- Thickening of the muscle that the nerve pierces.
- Trauma to the area that the nerve supplies, e.g. elbow fracture or large bruise.

There may be no cause found.

SIGNS AND SYMPTOMS

The symptoms that can occur with this condition are:

- Numbness - in the skin of the lower leg and foot.
- Tingling – similar to pins and needles, this occurs in the same region as the numbness and,
- Weakness of the lower leg muscles causing a foot drop which can cause the foot to trip on the ground or uneven surfaces.

INVESTIGATIONS

The most common test performed is a:

- Nerve conduction study - which looks at the degree of compression on the nerve and whether there has been any changes within the nerve due to the compression.

Occasionally an:

- MRI or further images of the spine may be performed to rule out any causes higher up compressing the nerve.