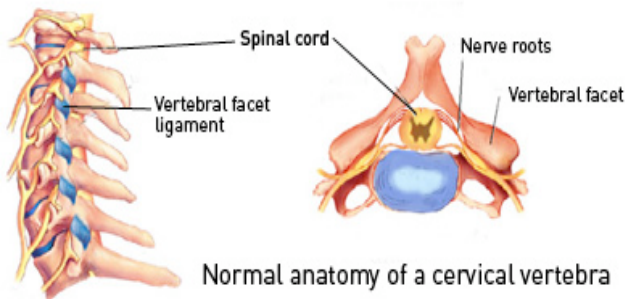




Cervical Canal Stenosis



The cervical spine is subject to the wear and tear of the entire spine. It does not bear the load of the lumbar spine but does not get any support from the ribs. Subsequently disease is more common than the thoracic spine, but much less than the lumbar spine (lower back). Degenerative arthritic changes in the cervical spine secondary to ageing may result in bony and soft tissue overgrowth with resultant encroachment on the cervical spinal canal, termed cervical canal stenosis. In addition any disc prolapse may lead to further narrowing of the spinal canal.

CAUSE

Cervical canal stenosis is a degenerative disease. A proportion of the population have a congenitally small cervical canal which predisposes them to canal stenosis. Previous neck trauma or chronic manual work may also predispose to the development of cervical canal stenosis

SIGNS AND SYMPTOMS

A variety of symptoms are present with cervical canal stenosis due to degenerative changes with bones and joints and pressure on neurological structures as a result. These may progress with time and include:

- Neck pain.
- Radicular pain (radiculopathy).
- Myelopathy.

Neck Pain

Chronic neck pain radiating to the back of the head and down between the shoulder blades may be present. This may be worsened with neck movements. Whilst this pain may be intense, unless there is marked instability in the cervical spine there is usually no operative neurosurgical treatment indicated

Radiculopathy

Stenosis in the lateral regions of the cervical canal may result in pressure on the exiting nerve roots. The nerve roots supply power and sensation to the

arms and severe radicular pain (pain shooting into the arm) may occur in a specific nerve distribution. Numbness and tingling may also occur in the same region.

Myelopathy

Stenosis in the central regions of the cervical canal may result in pressure on the spinal cord. This may result in disruption of the nerve signals to the legs and cause spastic legs, hyper-reflexic legs and difficulty walking (myelopathy). It may also result in radicular symptoms with pain shooting into the arms, torso or legs. There may also be loss of control of the bowel and bladder function.

Severe cervical canal stenosis may render the patient at high risk of paralysis from an acute event like trauma or an acute cervical disc prolapse.

INVESTIGATIONS

- Plain x-rays – these are usually taken to rule out any fracture or malalignment. Dynamic x-rays taken in flexion and extension may be performed to document any instability. Plain x-rays do not give any information on nerve root or spinal cord compression.
- CT C-spine – this is usually the first investigation ordered by the GP for neck pain/radicular symptoms. It gives an indication of the severity of any canal stenosis. Occasionally it is combined with a myelogram to demonstrate any functional compression/obstruction.
- MRI C-spine – this is the gold standard in looking for cervical canal stenosis and to delineate the degree of nerve root or spinal cord compression.

The presence of intractable radicular pain and neurological deficit is an indication for operative neurosurgical treatment. Neurosurgical treatment aims to relieve symptoms via decompressing nerves with or without stabilising the spine (fusion). Myelopathy is difficult to reverse and decompression for this symptom is aimed at preventing worsening of symptoms rather than improvement back to normal.

