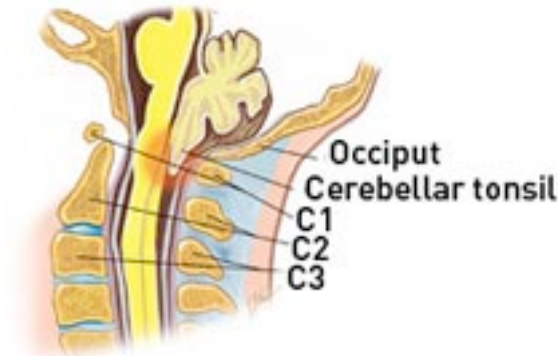




Posterior Fossa Decompression of Arnold Chiari Malformation



Copyright © Oxford University Press, *Do you really need back surgery?* www.backpain-guide.com

OPERATION

Posterior fossa decompression of Arnold-Chiari malformation

The operation to decompress the lower brain stem and cerebellum will require a general anaesthetic. Hair over the occiput will be shaved and the patient is positioned on their stomach giving access to the back of the skull and neck. An incision is then made in the midline of the neck to expose the skull and neck bones covering the brain stem and cerebellum. Careful removal of a window of bone at the base of the skull is then performed using a high speed drill. A laminectomy of the upper 2-3 cervical spine vertebrae may also be performed. The bone removed is not replaced, leaving a spacious cavity.

Frequently the lining of the brain and spinal cord (dura) is then opened allowing further decompression. A graft is then stitched into place. This graft may be synthetic or may be taken from the patient's own thigh via a separate incision. The wound is then stitched together and the patient is awoken. The procedure takes around two hours to perform. Postoperative wound pain is an issue but is easily treatable. Patients usually ambulate and resume a normal diet the following day.

Neurosurgical treatment of syrinx

In the event there is no improvement of symptoms following a posterior decompression of Arnold-Chiari malformation and there is a persistent syrinx, an operation to shunt the syrinx may be performed. The options for shunting include:

- Syringo-arachnoid shunt.
- Syringo-peritoneal shunt.
- Syringo-atrial shunt (rare).

This will involve a general anaesthetic and the patient lying face down (prone) on the operating table. A small incision is made in the midline of the spine directly over the syrinx as identified using radiological guidance. The dura is then opened and spinal cord visualised. A midline incision is made over the thinnest part of the spinal cord to enter the syrinx. A Silastic catheter then inserted and placed in the subarachnoid space or tunnelled under the skin to the peritoneum, depending on the operation planned. The dura is then closed with stitches and the skin incision stitched close.

It is expected that the neck and occipital pain should resolve as the wound heals. Neurological symptoms present before the operation may recover in time with targeted physiotherapy and rehabilitation. The main aim of the operation though is to prevent further deterioration of function by wide decompression of the affected brain stem and upper spinal cord.

Risks of the procedure:

The risks of this operation includes the following. A detailed discussion with your surgeon is recommended prior to surgery.

- Infection: may be superficial or deep involving bone and /or disc space.
- Infection or blockage of the shunt tubing requiring replacement of the shunt.
- Bleeding: may be superficial bruising or a deeper collection.
- Injury to a nerve root resulting in weakness +/- numbness of an upper limb.
- Injury to the cerebellum resulting in dizziness, clumsiness and in-coordination of the limbs.
- Injury to the spinal cord which could result in weakness or paralysis of the arms and legs.
- Damage to the dura resulting in leakage of fluid to the surrounding tissue (rare). If a leak persists, headaches may occur & very rarely a second operation may be required.
- Instability resulting in movement of the bones which may require a second operation to correct.
- Incorrect placement of the shunt tubing requiring a second operation to reposition it.
- Coma or death.

Follow-up MRI scans will be performed to demonstrate the degree of decompression once you have recovered from the operation. The MRI scan will also show the progress of any secondary hydrocephalus which may resolve with decompression. Occasionally a ventriculo-peritoneal shunt may need to be performed for persistent hydrocephalus.