



## Lumbar Canal Stenosis

The spinal canal is made up of the bony ring of a vertebra and contains the spinal cord and nerve roots. There is normally free passage of the spinal canal contents through the canal. Lumbar canal stenosis occurs when the bony ring of the lumbar vertebra is affected by degenerative changes of osteoarthritis. This may result in overgrowth of bone or bony joints and thickening of supporting ligaments. Eventually the degenerative changes encroach on the spinal canal and lead to narrowing called stenosis.

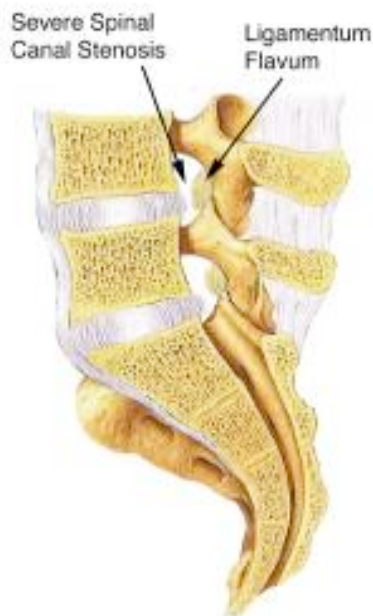

Image: © Oxford University Press,  
Do you really need back surgery? [www.backpain-guide.com](http://www.backpain-guide.com)

### CAUSE

There are 3 factors that contribute to lumbar canal stenosis, namely:

- Bony overgrowth.
- Ligamentum flavum hypertrophy, and
- Disc prolapse.

Most cases of lumbar canal stenosis are due to progressive bony and soft tissue overgrowth from arthritis. Certain members of the population are more at risk than others of developing lumbar canal stenosis. Other people have a congenitally small lumbar canal which predisposes them to lumbar canal stenosis. Occasionally an acute disc prolapse will exacerbate any pre-existing lumbar canal stenosis causing neurological symptoms.

### SIGNS AND SYMPTOMS

A variety of symptoms are present with lumbar canal stenosis due to the degenerative changes with bones and joints, and any pressure that may occur on neurological structures as a result. These include:

- Back pain.
- Sciatica.
- Neurogenic claudication.
- Cauda equina syndrome.

#### Back Pain

Chronic low back pain radiating to the hips and buttocks may be present. This may be worsened with any back movements. Whilst this pain may be intense, unless there is marked instability in the lumbar spine there is usually no operative neurosurgical treatment indicated.

#### Sciatica

Stenosis in the lateral (side) regions of the lumbar canal may result in pressure on the exiting nerve roots. The nerve roots supply power and sensation to the legs and severe radicular pain (pain shooting into the leg) may occur in a specific nerve distribution. Numbness and tingling may also occur in the same region.

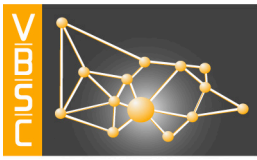
#### Neurogenic claudication

This is pain running down both legs that get worse with walking and limits the distance you can walk. It is usually a cramp-like pain but occasionally may be burning in sensation. It is due to central lumbar canal stenosis that causes pressure on the cauda equina as you move.

#### Cauda equina syndrome

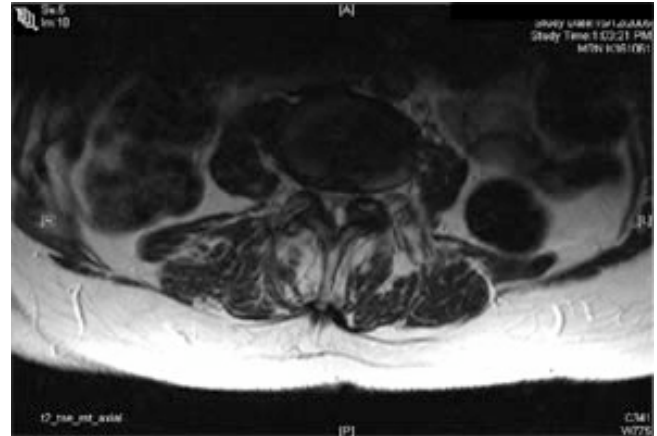
Persistent severe pressure on the cauda equina may result in cauda equina syndrome. This includes:

- Numbness around the bottom and anus.
- Impotence or sexual dysfunction.
- Loss of bowel or bladder control.



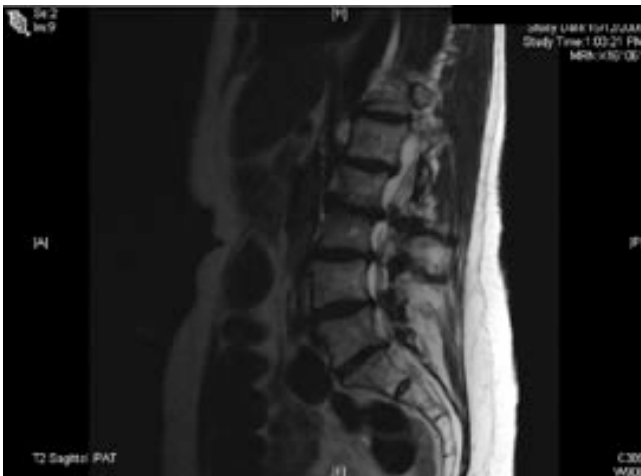
## INVESTIGATIONS

- Plain x-rays – these are usually taken to rule out any fracture, malalignment or pars defect. Dynamic x-rays taken in flexion and extension may be performed to document any instability. Plain x-rays do not give any information on nerve root or spinal cord compression.
- CT lumbar-spine – this is usually the first-line investigation ordered by the GP for low back pain/radicular symptoms. It gives good visualisation of the bony structures and an indication of the severity of the canal stenosis. Occasionally it is combined with a myelogram to demonstrate any functional compression/obstruction.
- MRI lumbar-spine – this is the gold standard in looking for lumbar canal stenosis and to delineate the degree of nerve root or cauda equina compression.



*Axial MRI demonstrating lumbar canal stenosis through L4/5*

The presence of intractable radicular pain and neurological deficit is an indication for operative neurosurgical treatment. Neurosurgical treatment aims to relieve symptoms via decompressing nerves and with or without stabilising the spine (fusion).



*Sagittal MRI demonstrating lumbar canal stenosis at multiple levels*