

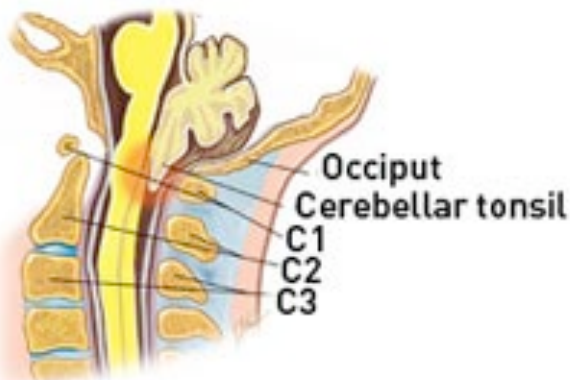


Arnold Chiari Malformation

Arnold-Chiari malformation is primarily a problem where the skull attaches onto the spine, medically termed the cranio-cervical junction. In such cases there appears not enough space at this site to accommodate the base of the brain, the brain stem and cerebellum. The cerebellum and lower brain stem are compressed into the spinal cord canal with the spinal cord.

There are various amounts of compression observed which correlates with the amount of brain stem and cerebellum protruding into the spinal canal. Likewise symptoms parallel the degree of compression. Due to its presence at birth symptoms occur in children through to young adults.

Occasionally a cystic cavitation of the spinal cord (syrinx) may also form at the cervico-occipital junction. This may in itself cause the same symptoms as the Chiari malformation.



© Oxford University Press,
Do you really need back surgery? www.backpain-guide.com

CAUSE

This is a condition which people are born with, and progresses with development. It is graded in severity depending on the amount of cerebellar tonsils that have been pushed into the spinal canal, more being more severe.

Occasionally secondary Arnold-Chiari malformation may occur due to raised intracranial pressure from a mass lesion eg tumour. In these cases the cerebellar descent is caused by the raised pressure above and may resolve with treatment of the primary cause.

SIGNS AND SYMPTOMS

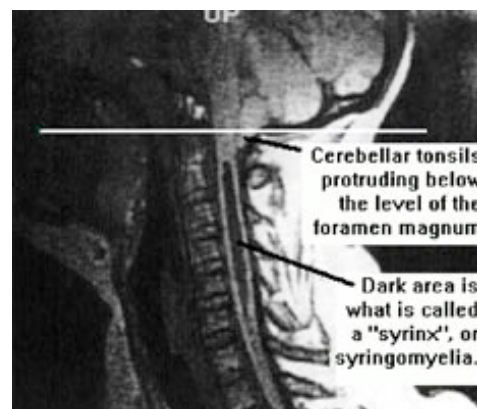
Patients may exhibit a variety of symptoms.

- Headache – this is common at the back of the head.
- Neck Pain – this is often severe and radiates to the top of the head
- Neurological deficits - jerky eye movements (nystagmus), swallowing difficulties, and frequently stiff or spastic arms are seen in infants. In older patients stiffness of the lower limbs can develop as well as wasting of the muscles in the hands. A loss of sensation across the shoulders and arms may also occur.

INVESTIGATION

Arnold-Chiari malformations are diagnosed by radiological imaging of the brain and cervical spine.

- A CT scan is often performed giving views of the bony compartments of the skull overlying the brain stem.
- An MRI scan is essentially to demonstrate the degree of compression, presence of a syrinx and also to investigate any underlying causes or resultant effects. Occasionally mass lesions (tumours, vascular malformations) in the brain itself may lead to increased pressure inside the skull and herniation of the brain stem into the cervical spine canal. Also secondary hydrocephalus may be present as a result of the brain stem compression and obstruction to flow of cerebrospinal fluid. It is also used post-operatively to monitor the amount of decompression and recovery of the syrinx.



Surgical treatment involves operating to create more room at the back of the skull and upper spine. This procedure will decompress the brain stem and upper spinal cord. Shunting the syrinx may also be required in the future should symptoms not improve.