



The use of investigations are key to diagnosing and managing complex neurosurgical conditions. These range from routine general bloods tests (ie. full blood count, electrolytes, clotting times), specific blood tests (including pituitary function tests and tumour markers) and radiological investigations.

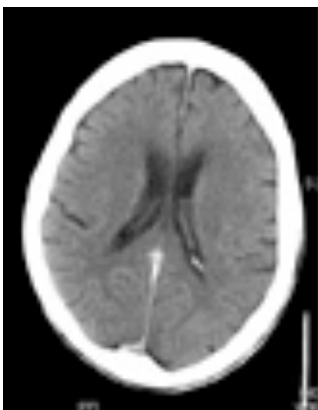General Blood Tests

The full blood count and coagulation screen are essential prior to most neurosurgical interventions to ensure minimal risk of haemorrhage or infection. An electrolyte screen is also frequently performed to monitor the fluid balance of your body and minimize brain swelling and renal dysfunction. Occasionally your blood type will be tested especially in conditions that might require the need of a blood transfusion. Each test performed is specifically geared at gaining important information relevant to providing the best ongoing care for each patient.

Computerised Axial Tomography – CT Scan

The CT scan remains the most widely used form of imaging presently used for the diagnosis of pathology in or around the brain or spinal cord. This is due to its wide availability and lower cost compared to MRI. The classic CT scanner is able to generate cross-sectional information of the region being imaged in different angles or gantries. The newer multi-slice CT scanners available to the VBSC at St Vincent's Hospital are also able to reconstruct 3D-images from these cross-sectional slices giving greater clarity and accuracy of image.

CT – Head



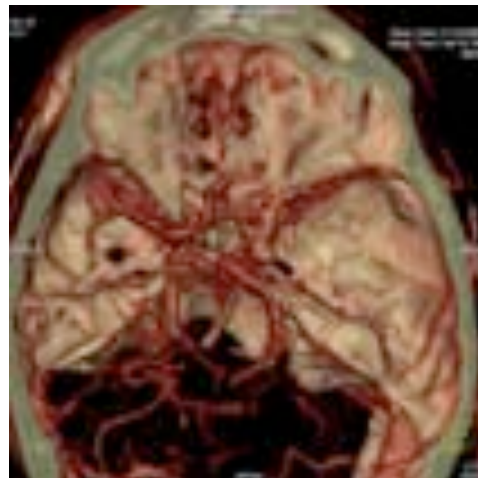A CT of the head can be prescribed by any registered doctor. Your general practitioner or local emergency department will arrange this if it is relevant. CT head scans are generally ordered in cases of head trauma, persistent headache, stroke-like symptoms (weakness, numbness, visual disturbance, slurred speech), altered conscious state, personality change or epilepsy.

These scans may appear normal or detect varied lesions from traumatic bleeds, intracranial tumours, stroke and cerebral aneurysm haemorrhage.

A CT scan of the head takes around 15 minutes. You will be transferred to the CT table which is then advanced into the CT scan aperture. This aperture contains the rotating x-ray tube that delivers low levels of radiation through the region of interest. You may notice the CT aperture moving into different positions and this is to obtain images at different angles. There will be a low humming whilst the images are acquired. Occasionally an intravenous injection of contrast may be required. This will be injected by the radiologist on duty and sometimes causes hot flushes though the body. All the images obtained are then sent to a computer workstation and analysed by the neuroradiology team.

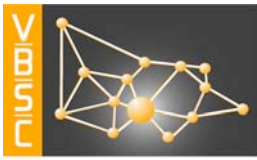The CT scan tends to be better tolerated than the MRI because of the shorter scanning time required. Also in some respects it is more sensitive if lesions involve the bone.

CT Angiogram

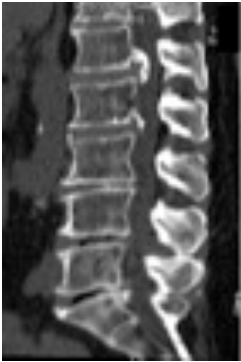

A newer form of imaging is performing an angiogram through the CT scan. This involves an intravenous injection, which can give excellent blood vessel anatomy of arteriovenous malformations (AVM) or cerebral aneurysms. This is useful as an aid in the diagnosis and potential treatment of these lesions.

Similarly CT angiogram can be of benefit for treatment of brain tumours especially in delineating large feeding vessels and minimizing bleeding risks in surgery

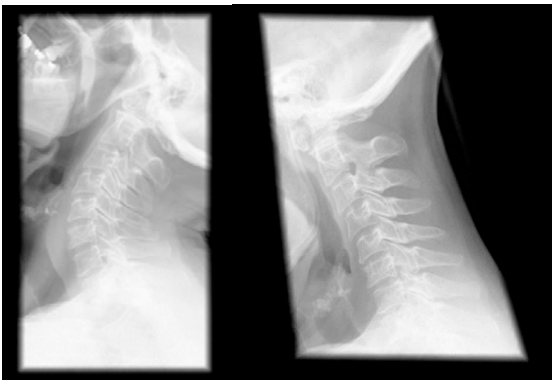


CT – Spine



Use of the CT scan in the diagnosis of degenerative spinal conditions is an excellent screening process, which is frequently performed by the family general practitioner. This can identify disc prolapses and potential compression of adjacent nerve roots or spinal cords. Also lesions in the bone themselves can be readily identified with the use of the CT scan. In the field of traumatic injury to the spine a CT scan through a rapid multi slice machine can be readily obtained with accurate reconstruction views performed in several planes.

Plain Films

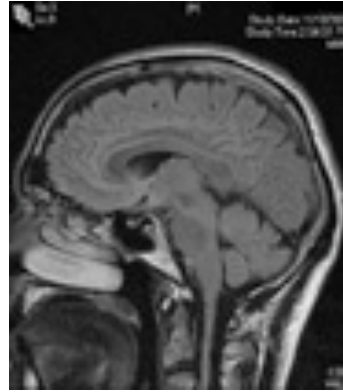


Left: Cervical extension Right: Cervical flexion

Plain Films may be taken of the Cervical, Thoracic and Lumbar Spine. You will be required to bend forwards and backwards for these scans. These will determine any instability in the spine.

Magnetic Resonance Imaging (MRI)

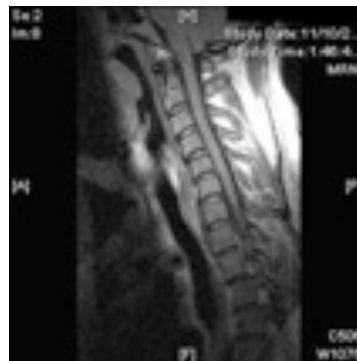The MRI is an excellent investigative tool in the diagnosis of neurosurgical problems. This involves placing the patient in a strong magnetic field which causes specific signals to be obtained from underlying tissues. The MRI is excellent for looking at brain tissue, spinal cord, nerve roots and peripheral nerves. This technique is readily available in larger metropolitan hospitals although cannot be used in patients who have pace makers, foreign metallic bodies in the eye, cochlear or ear implants or other metallic/electronic devices.



Careful consideration of the suitability in any of these instances needs to be discussed with the organising specialist.

The MRI scan is performed in a tunnel like machine that has the potential to induce claustrophobia. This is relatively frequent in the older machines occurring in up to one quarter of people. In the more recently available machines, the length of the tunnel has been decreased to six feet and the potential for claustrophobia to occur is greatly decreased.

The scan time is in the vicinity of 20-30 minutes to acquire the necessary images.

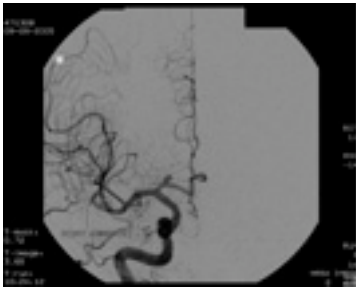


Additional studies can look specifically at the blood vessels in and around the base of the brain for the diagnosis of cerebral aneurysms or arteriovenous malformation. Of particular benefit is the exclusion of other conditions which may cause similar symptoms, these include multiple sclerosis, congenital abnormalities of the brain or spinal cord or infections. Thus the MRI scan gives a more accurate picture of the underlying nerve tissue although takes somewhat longer to perform than the more readily available CT scan.

The MRI scan can also be utilised to look for problems or pathologies in the shoulders, hip or knees. Any soft tissue of the body may be readily seen through the use of MRI scan.



Cerebral Angiography – Digital Subtraction Angiogram



A digital subtraction angiogram involves the introduction of a catheter into the major artery leading to the leg. This is performed by a local anaesthetic in the groin and an arterial puncture into the femoral artery. A catheter is carefully threaded by a radiologist in the x-ray department under x-ray control, up the large vessel at the back of the body (aorta) to position the catheter in the vessels at the base of the neck.

Intra arterial contrast is then injected rapidly over 3 – 4 seconds and an x-ray camera takes rapid six sequence photos as the contrast passes in normal blood flow through the arteries of the brain. Using several angles the vessels can be closely studied to look for any irregularities or potential aneurysms. Embolisation of vessels leading to vascular malformations or large tumours may also be performed through this technique.

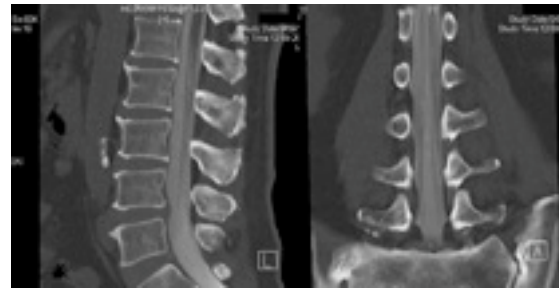
This procedure may at the time of contrast injection create a flushed sensation to the face or a metallic taste in the tongue. A person should be well hydrated before proceeding to his type of angiogram. In the presence of a past history of migraine the intra venous contrast can cause the precipitation of spasm to the underlying vessels with secondary transient stroke like symptoms. This must be discussed thoroughly before the procedure.

The overall risk of a stroke occurring with the use of an angiogram is approximately 0.5% although might be slightly higher if a person already has hardening of the arteries bleeding to the brain.

The availability of CT angiogram with improving accuracy is enabling digital subtraction angiogram to be used on a slightly less frequent basis. However at this point in time the use of a catheter angiogram remains the goal standard for best identification of the underlying vessels.

Occasionally an angiogram of the spinal vessels is also performed. This involves the same procedure as a cerebral angiogram excepting the radiologist enters spinal vessels coming off the aorta and does not image the blood vessels at the base of the neck.

CT – Myelogram



A CT myelogram may be performed if an MRI scan is contraindicated or fails to show a specific pathology in the spinal column.

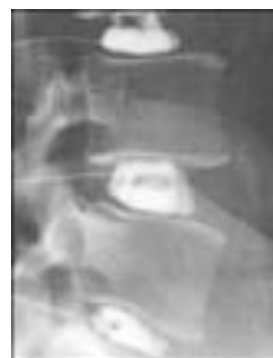This procedure is performed by the neuroradiologist in the x-ray department.

A myelogram involves a inserting a spinal needle under local anaesthetic into the spinal canal and injecting contrast fluid into the spinal canal.

Plain x-rays in 2 planes are taken to identify any obstruction to free flow of contrast within the spinal canal. The needle is then withdrawn and a CT scan performed allowing accurate visualization of the spinal canal and nerve roots. The table may be tilted during this procedure to ensure the contrast flows to the region of interest.

A myelogram may be performed in the lumbar spine or cervical spine (neck). Whilst uncomfortable it is rare for pain to be experienced. You will be required to lie flat following the procedure which takes approximately 1 1/2 hours to perform.

Discogram



Copyright © 2003 Pain Management Center, www.thepainmd.com

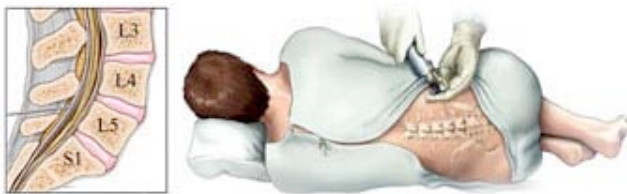A discogram involves performing a needle puncture of an intervertebral disc in the x-ray department by a specialist radiologist. This procedure is used to more accurately diagnose which disc in the lower spine is causing pain where there are several discs on an MRI scan which may appear to have degenerative desiccation or wear and tear change.



In the x-ray department whilst the patient is lying on their side a needle is carefully inserted through the skin after local anaesthetic has been infiltrated. This needle is passed into the disc space. Normally three discs are investigated over the one sitting to allow comparison between more severely affected discs and those which are essentially normal. Contrast material is injected into the disc space along with other solutions to ascertain which precipitates pain and also what the disc looks like on a CT scan after this procedure has been performed.

The use of a CT discogram will be discussed by your specialist and in the presence of an available MRI scan is less likely to be utilised in this day in age.

Lumbar Puncture



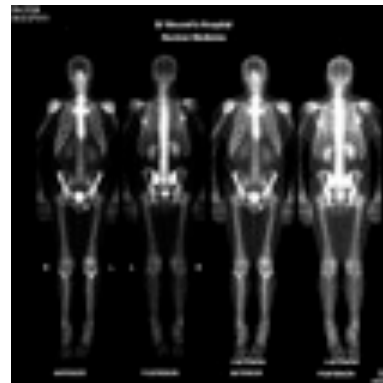Copyright © 2004 Nucleus Medical Art, Inc. All rights reserved.
www.nucleusinc.com

A lumbar puncture is a procedure whereby a small needle is inserted into the spinal canal of the lower spine. It is used in neurosurgery to easily obtain a specimen of cerebrospinal fluid for identification of infection, tumour markers/cells, bleeding or other neurological conditions.

The procedure is usually performed on your side or sitting up in a sterile fashion. Local anaesthetic will be injected into the skin after it has been cleansed by antiseptic. A spinal needle is then advanced slowly between the bony spinous processes of the spine to enter the spinal canal. There will be free flow of cerebrospinal fluid from the needle which will be collected for further analysis. A pressure monitor will also be attached to measure the pressure of the cerebrospinal fluid. The needle will then be removed and a small bandaid placed over the entry site. You will be required to lie flat for 4 hours following the procedure.

Occasionally it will be necessary to continuously monitor the pressure of the cerebrospinal fluid. In these instances a catheter will be inserted through the lumbar puncture and connected to an external drainage system. This is called a lumbar drain.

Bone Scan



A bone scan is a nuclear scanning test that specifically targets areas of bony activity. It is ordered by the neurosurgery team to investigate bony infections (osteomyelitis), traumatic spinal fractures and metastatic tumours.

The scan performed in the radiology department by a nuclear medicine technician or radiologist. A radioactive tracer specific to bone is injected and given around 3 hours to circulate through the body. The actual bone scan itself is performed after this time using a large scanning camera positioned directly above yourself on the scanning table. Scanning takes around 1 hour. The camera picks up radiation released by the injected tracer, producing relevant images of the bony skeleton. This information is then analysed by a nuclear medicine specialist.

It is important to keep well hydrated whilst waiting for the tracer to circulate through the body following the initial injection to wash-out excess radioactive particles. This test is contra-indicated during pregnancy.

Nerve Conduction Studies

Common conditions diagnosed by nerve conduction studies include carpal tunnel disease, tardy ulnar nerve and meralgia paraesthetica. It is indicated if you have pain, tingling, numbness or weakness in the limbs.

The electrophysiology department is located on the 6th floor of St Vincent's Hospital. The procedure takes around 45-50 minutes to perform and you are able to return home immediately after the test. Each test involves the placement of small needles over the nerve of interest. A short electrical current is then applied to test the nerve function but causes only minimal discomfort. The results are then read by a neurologist and take several days to a week to return.