



## Traumatic Spinal Condition

Serious injury to the spine is a major problem and involves significant proportion of the public health budget.

There are various factors that are considered in a patient who presents with a possible traumatic spinal injury:

- Damage or pressure to the spinal cord or spinal nerves.
- Instability of the vertebral column due to fractures or ligamentous injuries.
- Pain due to the spinal injury.

The mechanisms of Spinal cord injuries are:

1. Compression or distraction of the spine
2. Rotation
3. Shearing of the spine.
4. Combination of all three mechanisms.

### SIGNS AND SYMPTOMS

A variety of symptoms are present with traumatic spinal injury. These include:

- Neck or Back pain.
- Pain, weakness or numbness in arms or legs.

#### Neck or Back Pain

Acute neck or back pain is very common after a traumatic spinal injury. It can be due to a number of causes from spinal fractures, ligamentous injuries or soft tissue injuries. There will often be associated muscle spasm, aimed at limiting movement of the spine and relieving pain.

#### Pain, weakness or numbness in arms or legs

A fracture with bone movement, disc rupture or blood clot may result in pressure on the exiting nerve roots or spinal cord. The nerve roots supply power and sensation to the arms or legs may occur in a specific nerve distribution. Numbness and tingling may also occur in the same region.

### INVESTIGATIONS

- Plain x-rays – these are taken to show any fracture or malalignment. Dynamic x-rays taken in flexion and extension may be performed to document any instability. Plain x-rays do not give any information on nerve root or spinal cord compression.
- CT spine – this is usually ordered for neck or back pain and neurological symptoms. It gives good information fractures present and bony alignment but often fails to demonstrate any ligamentous or spinal cord injuries.
- MRI spine – this is the gold standard in looking for ligamentous injuries and to delineate the degree of nerve root or cauda equina compression.

### TREATMENT

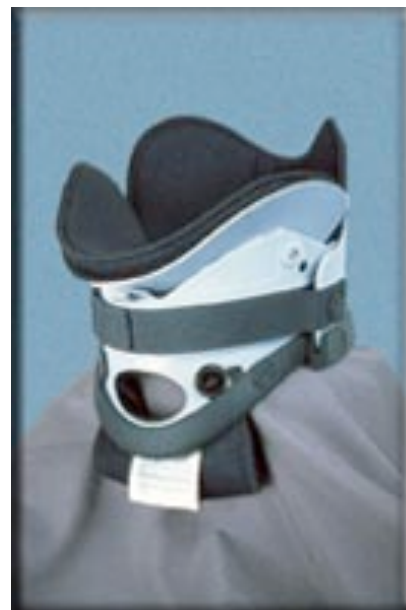If a spinal fracture or ligamentous injury does occur there are a number of possible treatments.

#### Conservative

If the spinal fracture is stable often pain relief is only required.

#### Collar/brace

These give support to the fracture and aim the healing process similar to a plaster cast. There are a number of different collars or braces available.



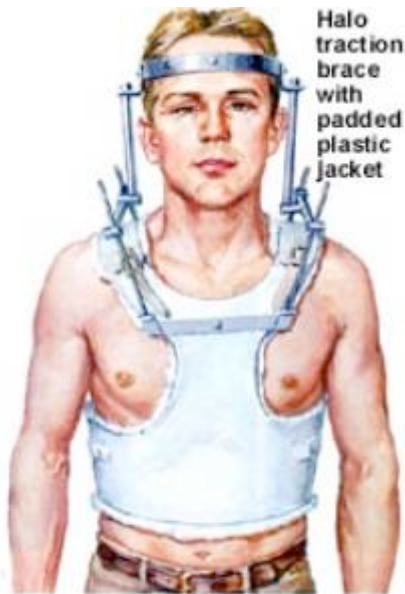
Copyright © [www.orthomed.co.za](http://www.orthomed.co.za)



## TREATMENT

### Halo thoracic Brace

If the fracture is too unstable within the neck often this brace is applied which has four pins that are attached to the skull. This gives much more support than the collar.



Copyright © [www.spineuniverse.com](http://www.spineuniverse.com)

### Spinal fusion

If the fracture is unlikely to heal with a brace often an operation is performed where screws and rods may be inserted to aim the long term healing of the fracture.

If there has been damage to the spinal cord or nerves then an operation maybe performed to relieve any pressure that may aid any improvement in weakness or sensory problems to the arms or legs. This will be discussed with your neurosurgeon. If a significant spinal cord injury has occurred then the patient may be transferred to a spinal injury unit at a designated hospital due to the extra care needed to look after these patients. There are a number of different operations that can be performed depending on the location and type of fracture which your Neurosurgeon will discuss with you.