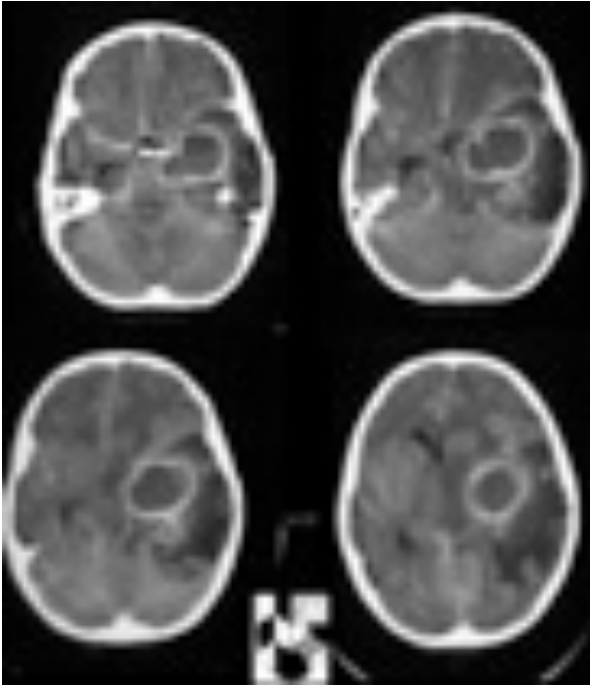




## Brain Abscess



A brain abscess is a localised infection within the brain substance containing bacteria or other microbes. The body forms a protective barrier around the infection however the abscess can still expand and cause a reactive swelling in the surrounding brain.

### CAUSES

A brain abscess may develop from one of three routes:

- Direct spread from adjacent infected regions ie infection in the ear, the eye or the sinuses.
- Spread from distant infected regions through the bloodstream eg. urinary tract, lung and bone infections.
- Direct implantation of bacteria into the brain substance eg. post-trauma, skull fractures, surgery.

### SIGNS AND SYMPTOMS

People with brain abscesses are generally very sick. They may show:

- Systemic symptoms.
- Symptoms related to raised intracranial pressure and
- Symptoms related to localized pressure.

#### Systemic symptoms

There will be normal signs of infection with swinging fevers, hot/cold flushes and drenching sweats.

#### Raised intracranial pressure

Headaches, nausea and vomiting may occur from raised pressure inside the skull from the expanding abscess mass.

#### Localised pressure

Specific signs of a brain abscess are dependent on the position of the abscess within the brain.

Seizures are common as is a progressive drowsiness and delirium. Neurological deficits like abnormal speech, weakness and numbness may occur.

### INVESTIGATIONS

#### Blood tests

There are no specific blood tests to diagnose an brain abscess although these may demonstrate the presence of the source of a brain abscess. Routine FBE, electrolytes and clotting profiles will be performed prior to operative removal of a brain abscess. The inflammatory markers (CRP and ESR) will be measured as a marker of the severity of the infection.

#### Septic screen

This will include at least 3 blood cultures.

#### Radiological tests

- CT head – a CT head with contrast is diagnostic of a brain abscess.
- MRI head – this gives further information with regards to possible sources of the abscess as well as being able to demonstrate smaller separate abscesses not seen on CT.