



Microvascular Decompression of Trigeminal Neuralgia

The options for treatment of a Cavernous Angioma (Cavernoma) include:

- Operative intervention and resection of the cavernoma.
- No treatment.

Trigeminal neuralgia is usually treated with medications such as Tegretol or Gabapentin.

The indications for neurosurgical intervention are:

1. Severe intractable pain.
2. Inability to eat/swallow.
3. Failure of medical treatment.

OPERATION

The options of neurosurgical treatment include a major operation (microvascular decompression of the trigeminal nerve) and several minor procedures (radiofrequency ablation or balloon occlusion).

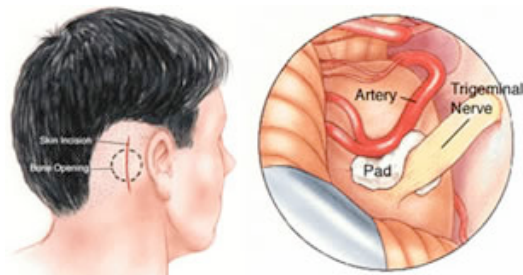
Microvascular decompression of trigeminal nerve

The major operation involves the patient being put to sleep and an incision behind the ear on the same side as the pain. A bone window is created, craniotomy (replaced at end of operation). A microscope is used to identify the trigeminal nerve and the structure compressing it. This is usually the superior cerebellar artery. A piece of sterile felt or something similar is placed between the two structures ensuring separation (Micro-vascular decompression).

The operation takes approximately two hours, and patients wake up well afterwards. The medication is weaned down over several months. This procedure has a low long-term risk of recurrence, but is a big operation compared to the above minor procedures.

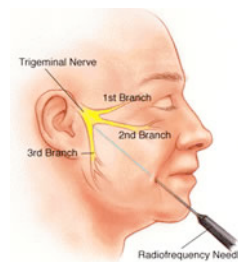
Radio-frequency ablation of trigeminal nerve

Under a local anaesthetic and a light sedation the trigeminal is targeted through a needle puncture on the side of the face adjacent to the lips.



Copyright 2005 , Department of Neurosurgery

X-rays are used to help direct us to the foramen ovale which is the exit point of the trigeminal nerve from the skull. Once the needle is in position, several short burst of radio-frequency are passed down the needle. The patient is awake at this stage and may report similar symptoms to their trigeminal neuralgia. After an appropriate period of time the needle is removed and a small dressing placed over the needle entry point. The patient is then discharged home.



Copyright 2005 , Department of Neurosurgery

Balloon-occlusion of the trigeminal nerve

This procedure is similar to the radio-frequency ablation of the trigeminal nerve with the exception that instead of radio-frequency bursts, a balloon is filled with a small amount of solution to compress the nerve. Again it is done under light sedation and the patient is discharged home on the same day.

Both of the minor procedures will result in profound facial numbness and there is a high rate of recurrence of symptoms in the 2-3 year period.

Risks of the procedures:

The risks of this operation includes the following.

A detailed discussion with your surgeon is recommended prior to surgery.

- Infection: may be superficial or deep.
 - Bleeding: may be superficial bruising or a deeper collection.
 - Cranial nerve damage: resulting in loss of hearing, facial weakness & numbness, double vision, hoarse voice, difficulty swallowing &/or impaired tongue movements.
 - Hydrocephalus - which may be temporary or permanent and may require a second operation.
 - Cerebrospinal fluid (CSF) leak through the wound and/or nose.
 - Headaches & neck pain.
 - Weakness, numbness, speech disturbance or paralysis (stroke like symptoms).
- * Coma or death.