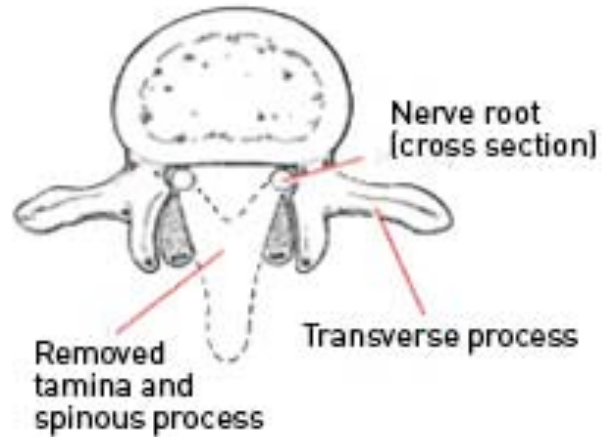
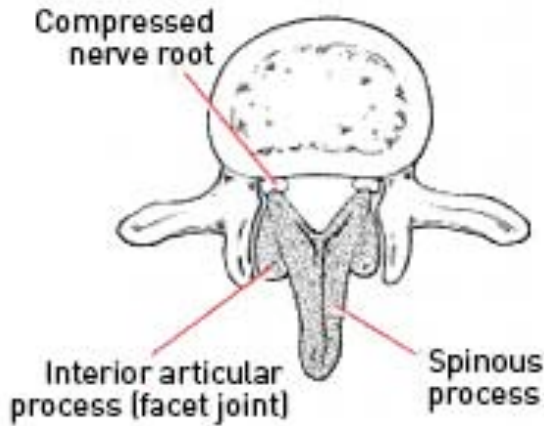




## Laminectomy & Evacuation of Epidural Abscess



The mainstay of treatment of epidural abscess is long term intravenous antibiotics followed by oral antibiotics. This will be prescribed in conjunction with the infectious diseases team of the hospital. Neurosurgical intervention is indicated in the event there is no diagnosis of the offending microbe causing the infection or if there is any signs of neurological deficit (weakness, numbness, tingling, loss of control of bowels or bladder).

### OPERATION

In general the operation will involve a laminectomy over the affected levels of the spine. The x-ray machine will be used to localize the correct level and a linear incision made over the spine. Frequently pus is encountered in the subcutaneous tissues as well as the epidural space and a sample is taken for microbiological growth and antibiotic sensitivities. A laminectomy is performed to decompress the spinal cord and drain the pus. Copious amounts of irrigation will then be used and a drain tube inserted over the spinal cord. The wound will then be closed with sutures.

### Risks of the procedure:

The risks of this operation includes the following. A detailed discussion with your surgeon is recommended prior to surgery.

- Bleeding: superficial bruising, or deep which may require a second operation because it has resulted impairment of function from spinal cord compression.
- Permanent neurological injury: weakness, numbness, paralysis due to injury of the neural structures (rare).
- CSF leak: leakage of the spinal fluid bathing the spinal cord which may require a second operation to close off.
- Recurrent epidural abscess, spread to adjacent structures (risks of disease process rather than operation) causing osteomyelitis, discitis or meningitis.

Despite good neurosurgical decompression of the spine, you will still require long-term antibiotics either intravenously or orally. This may be able to be given via Hospital in the Home but follow-up with regular blood tests and radiological imaging of the spine will be needed.