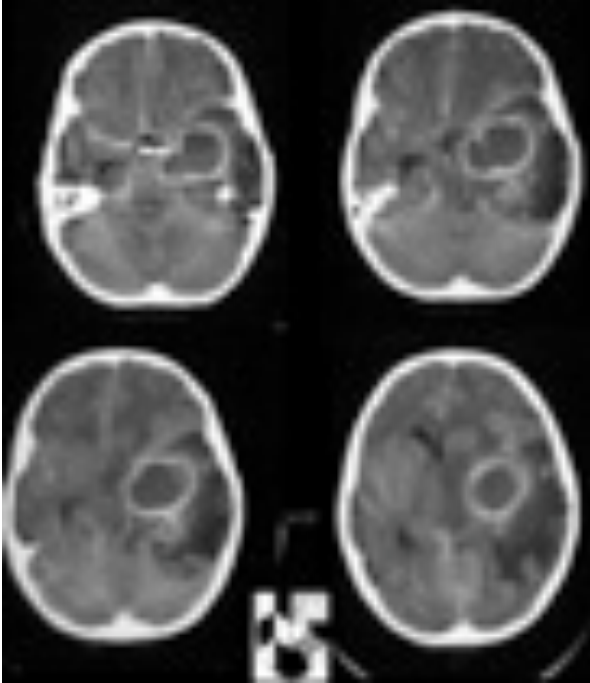




Brain Abscess



A brain abscess is a localised infection within the brain substance containing bacteria or other microbes. The body forms a protective barrier around the infection however the abscess can still expand and cause a reactive swelling in the surrounding brain.

CAUSES

A brain abscess may develop from one of three routes:

- Direct spread from adjacent infected regions ie infection in the ear, the eye or the sinuses.
- Spread from distant infected regions through the bloodstream eg. urinary tract, lung and bone infections.
- Direct implantation of bacteria into the brain substance eg. post-trauma, skull fractures, surgery.

SIGNS AND SYMPTOMS

People with brain abscesses are generally very sick. They may show:

- Systemic symptoms.
- Symptoms related to raised intracranial pressure and
- Symptoms related to localized pressure.

Systemic symptoms

There will be normal signs of infection with swinging fevers, hot/cold flushes and drenching sweats.

Raised intracranial pressure

Headaches, nausea and vomiting may occur from raised pressure inside the skull from the expanding abscess mass.

Localised pressure

Specific signs of a brain abscess are dependent on the position of the abscess within the brain.

Seizures are common as is a progressive drowsiness and delirium. Neurological deficits like abnormal speech, weakness and numbness may occur.

INVESTIGATIONS

Blood tests

There are no specific blood tests to diagnose an brain abscess although these may demonstrate the presence of the source of a brain abscess. Routine FBE, electrolytes and clotting profiles will be performed prior to operative removal of a brain abscess. The inflammatory markers (CRP and ESR) will be measured as a marker of the severity of the infection.

Septic screen

This will include at least 3 blood cultures.

Radiological tests

- CT head – a CT head with contrast is diagnostic of a brain abscess.
- MRI head – this gives further information with regards to possible sources of the abscess as well as being able to demonstrate smaller separate abscesses not seen on CT.